



PHLEBOLOGICAL REVIEW

PRZEGLĄD FLEBOLOGICZNY

Official Journal of the Polish Society of Phlebology



EFFECTIVENESS OF SCLEROTHERAPY IN THE TREATMENT OF HAEMORRHOIDS

Zbigniew Rybak¹, Andrzej Popow², Paweł Kuczewski², Piotr Korzekwa³

¹Experimental Surgery and Biomaterials Research, Wrocław Medical University, Poland

²Municipal Hospital in Hajnówka, Poland

³Częstochowa University, Poland

ABSTRACT

Objectives: This study was aimed at evaluating the effectiveness of sclerotherapy for the treatment of haemorrhoids with the use of a specially designed video anoscope.

Material and methods: We analysed the results of treatment for symptomatic haemorrhoids in 47 patients. There were 21 patients presenting with stage 1 and 2 of haemorrhoidal disease, who were managed with sclerotherapy, and 26 similar patients who were treated using other methods.

Results: At follow-up pain significantly decreased in patients managed with sclerotherapy, but it did not change significantly in patients managed with other methods. Similarly, quality of life significantly improved in patients managed with sclerotherapy and did not improve in the control group.

Conclusions: The results of sclerotherapy for grade 1 and 2 haemorrhoids are very promising. Sclerotherapy is a simple treatment modality, it is relatively inexpensive, it still requires doctor's expertise, and proper equipment should be used.

Key words: haemorrhoids, sclerotherapy, ultrasound guided foam sclerotherapy, polidocanol.

ORIGINAL PAPER

Phlebological Review 2016; 24, 1: 25–28
DOI: 10.5114/pr.2016.61535

Submitted: 9.02.2016

Accepted: 6.06.2016

ADDRESS FOR CORRESPONDENCE

Prof. Zbigniew Rybak
Experimental Surgery and Biomaterials
Research
Wrocław Medical University
Pasteura 1, 50-367 Wrocław, Poland
e-mail: zrybak@poczta.onet.pl

INTRODUCTION

Rectal haemorrhoids are extended, often swollen veins of the rectal plexus. Venous plexuses of the anus play an important role in anal continence, particularly regarding incontinence of flatus. Disorders of blood flow through these plexuses result in a dysfunction, generally defined as haemorrhoidal disease. Haemorrhoidal disease is an anatomical and clinical status of the haemorrhoids, which produces clinical symptoms and is the cause for seeking medical care [1]. Haemorrhoidal disease is a serious and embarrassing problem for many people. This disease affects approximately 5% of the population. Peak prevalence of the disease is observed between 45 and 65 years of age. In developed countries about 50% of the population will complain of haemorrhoids at some point in their lives. Hospital-based proctoscopic studies revealed prevalence rates of up to 86%, even if many of these patients remained asymptomatic [2].

Depending on the size of haemorrhoids, there are four clinical stages of the disease:

- enlargement of haemorrhoids, without external prolapse;
- haemorrhoids that prolapse during defecation, but reduce spontaneously;
- haemorrhoids that prolapse during defecation and must be manually reduced;

- haemorrhoids that cannot be reduced and often are thrombosed [3].

Other diseases of this area, such as: anal fissure, ano-rectal fistula, Crohn's disease, polyps, and neoplasms should be considered in the differential diagnosis. Symptoms of haemorrhoidal disease include:

- sensation of incomplete defecation;
- pruritus and burning sensation in the area of the anus;
- minor bleeding during defecation (blood in the stool is light-red; a presence of partially digested, dark-black, or almost-black blood is suggestive of another, usually more serious disease);
- prolapse of the haemorrhoids;
- pain, irritation, discomfort in the area of the anus;
- presence of mucous fluid in the anus [3].

There are several methods of treatment for haemorrhoidal disease:

A) Conservative treatment:

- veno-active medications administered locally and orally;

B) Surgical treatment:

- surgical excision, such as: Milligan-Morgan haemorrhoidectomy, stapled Longo procedure, and rarely performed Whitehead procedure,
- low-invasive methods:
 - Barron procedure,
 - sclerotherapy,
 - photocoagulation,

- laser coagulation,
- bipolar coagulation,
- monopolar coagulation (Hemoron),
- Morinaga procedure (Doppler-guided haemorrhoidal artery ligation).

In all surgical methods a diseased venous plexus is excised. Milligan-Morgan haemorrhoidectomy remains the most often used method. In the stapled Longo procedure venous plexuses are cut out with a fragment of the mucosa using a circular stapler. The Barron method is an office procedure comprising a ligation of the haemorrhoids with the use of elastic bands. In this method, in order to accelerate necrosis of ligated haemorrhoids, cryotherapy (external freezing) is often added to ligation.

Sclerotherapy of the haemorrhoids consists of injection of an obliterating agent into the submucosal space of the haemorrhoid, which evokes thrombosis of blood vessels and sclerosis of the connective tissue. A proctoscope that is dedicated to this procedure allows identification of lesions, and a needle incorporated into the instrument allows precise injecting under visual control. Usually 2% or 3% lauromacrogol is used as a sclerosant. Treatments are performed on an outpatient basis. With this method usually stage 1 and 2 haemorrhoids are managed, and selected patients presenting with stage 3 can also be included. The method is simple and does not require anaesthesia [3, 4]. Photocoagulation of the haemorrhoids utilises coagulator emitting infrared light that is applied in the area of haemorrhoidal bundle. Radiation causes inflammation and sclerosis. In a similar manner, haemorrhoids can be coagulated with use of laser with a wavelength of 940, 980, or 1470 nm. Energy is transmitted through the laser fibre in order to induce necrosis of the haemorrhoid and its fibrosis. Bipolar coagulation of the haemorrhoids exploits a radio frequency coagulation instrument, which is used to close haemorrhoids. A similar method is Hemoron, which utilises monopolar low-voltage diathermy. Then there is the Morinaga procedure, which consists of controlled ligation of haemorrhoidal arteries under Doppler guidance.




Fig. 1. Video anoscope used for sclerotherapy

AIM OF THE STUDY

This study was aimed at evaluation of the effectiveness of sclerotherapy for the treatment of haemorrhoids with the use of a specially designed video anoscope.

MATERIAL AND METHODS

We analysed the results of treatment for symptomatic haemorrhoids in 47 patients who responded to a questionnaire assessing postprocedural quality of life. There were 21 patients presenting with stage 1 and 2 of haemorrhoidal disease, according to the Parks classification, who were managed with sclerotherapy, and 26 similar patients, who were treated using other methods. The questionnaire consisted of two parts: the first comprised questions on patients' age, place of residence, weight and height, duration of the disease, clinical stage of the disease, and by whom the patient was managed before the procedure. The second part of the survey included specific questions on the evaluation of treatment and methods used in the treatment before the procedure, and on treatment performed in our centre (Surgical Department in Hajnówka). In addition, patients evaluated quality of life before and after the procedure and assessed their level of pain using the visual analogue scale (VAS).

The procedure was performed with the use of a surgical video anoscope (Fig. 1). Before the procedure an enema was performed to clean the rectum. After examination of the rectum with the anoscope, 1-2 ml of 3% lauromacrogol was injected into the submucosal space of each haemorrhoid. Anaesthesia during this procedure was not needed. Follow-ups, including control anoscopy, were performed two weeks after the procedure.

MATERIAL AND METHODS

The statistical tests used comprised: the Wilcoxon test with correction for tied ranks and correction for continuity to compare nonparametric variables in two dependent groups; and the ANOVA Kruskal-Wallis test for comparison of nonparametric variables in more than two independent groups, which was replaced by the univariate ANOVA for independent groups in the case of conforming data to the assumptions. Analysis of related nominal variables was conducted with the McNemar's test. Significance of the tests was set at $p < 0.05$. Statistical analysis was performed using the PQStat 1.3.0 package (PQStat Software, Poznań, Poland) and Microsoft Office Excel 2007 (Microsoft, Richmond, USA).

RESULTS

There were no complications associated with sclerotherapy in the studied group. Demographic characteristics of the patients are given in Figures 2-4. Of note,

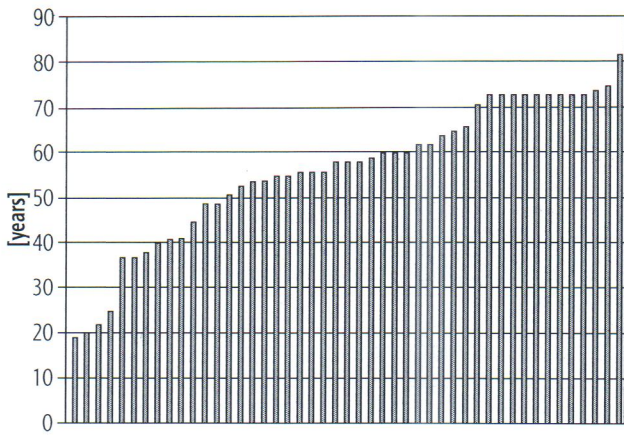


Fig. 2. Age of patients

there was a predominance of patients with vocational education. At follow-up, pain significantly decreased in patients managed with sclerotherapy (Fig. 5), but pain did not diminish significantly in patients managed with other methods (Fig. 6). Similarly, quality of life significantly improved in patients managed with sclerotherapy (Fig. 7) but did not improve in the control group (Fig. 8).

DISCUSSION

Surgical methods, such as conventional haemorrhoidectomy or stapled haemorrhoidopexy are widely used for the treatment of prolapsing haemorrhoids. Although surgery is more effective than pharmacological treatment, it is associated with a risk of severe complications. Low-invasive procedures, such as ligation with rubber bands or sclerotherapy, provide an alternative for surgery. Sclerotherapy is one of the oldest methods of treatment for haemorrhoids. Morgan (Dublin, then UK) described this method in 1869 and used for this purpose a mixture of 5% phenol in oil, 5% quinine, and urea. Nowadays a number of chemical substances are used for this procedure: phe-

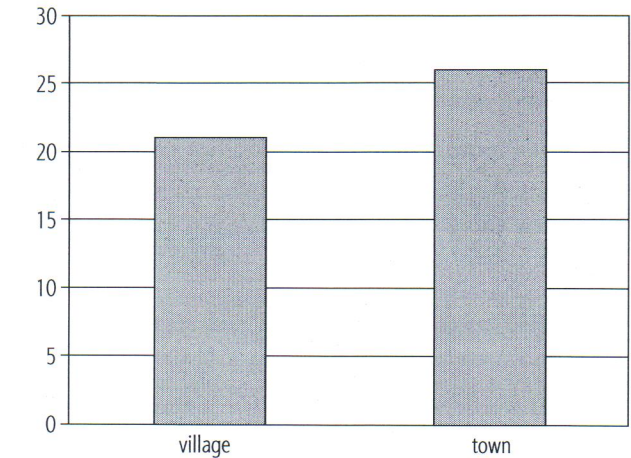


Fig. 3. Place of residence of patients: 1 – village; 2 – town up to 50,000 inhabitants

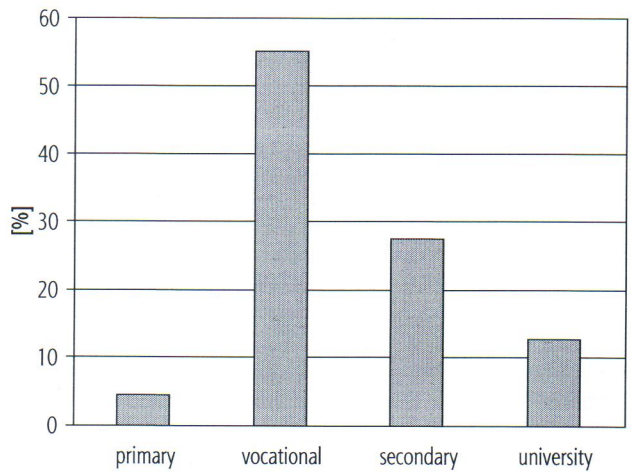


Fig. 4. Patients' education

nol, lauromacrogol, tetradecyl sulphate, and aluminium potassium/tannic acid. Sclerosing agent induces a rapid inflammatory reaction resulting in stasis of the blood and shrinking of haemorrhoidal nodules, followed by their

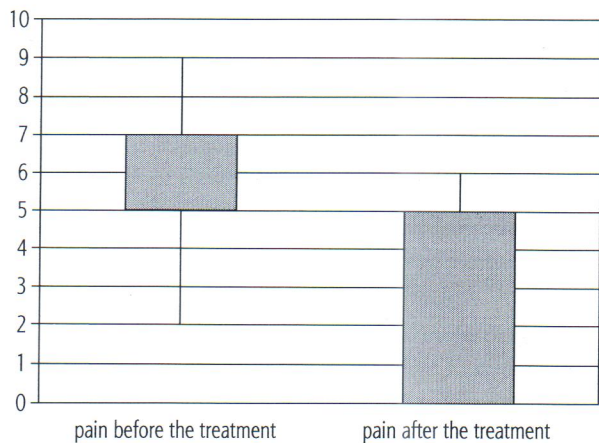


Fig. 5. Pain measured with VAS in patients managed with sclerotherapy

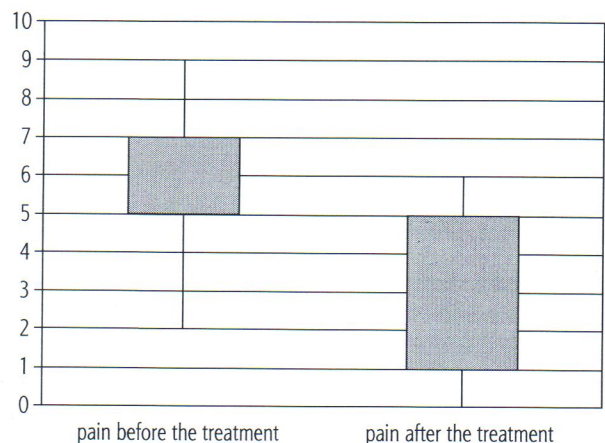


Fig. 6. Pain measured with VAS in patients managed with other methods (control group)

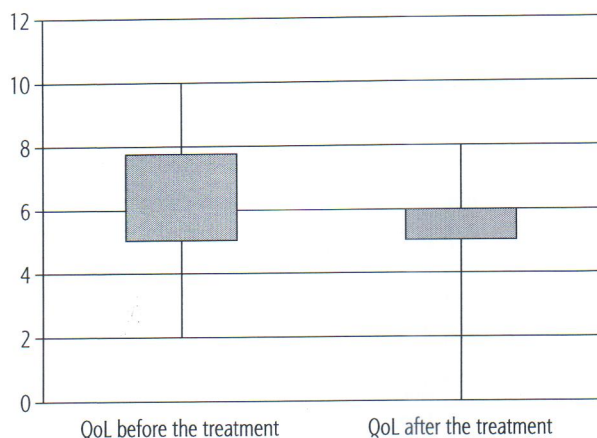


Fig. 7. Quality of life (QoL) in patients managed with sclerotherapy

fibrosis and fixation. Sclerotherapy of haemorrhoids is a safe procedure, and a specially designed anoscope prevents such complications as: prostatitis, local necrosis at the site of injection, or stricture of the anus.

The fact that there are many alternative methods for the treatment of haemorrhoids suggests that all of them are imperfect [3-6]. An ideal method should be both effective and low-invasive. Sclerotherapy for the treatment of stage 1 and 2 haemorrhoids seems to meet these criteria.

Tokunaga performed 784 sclerotherapies for haemorrhoids and compared this method with haemorrhoidopexy, which was performed in 118 patients. He concluded that haemorrhoidectomy, which is routinely used for the treatment of haemorrhoids, requires hospitalisation of patients and is often accompanied by pain. Sclerotherapy could be performed on an outpatient basis and is not associated with significant pain and other complications, while haemorrhoidopexy is a useful alternative method, which is also associated with low level of pain [7].

Khoury *et al.* performed a prospective trial on patients with 1 and 2 grade haemorrhoids. These patients were initially treated with pharmacological agents. Sclerotherapy resulted in clinical improvement or complete cure in 89.9% of the patients [8].

CONCLUSIONS

The results of sclerotherapy for grade 1 and 2 haemorrhoids are very promising. If compared to the control group, after sclerotherapy there was significantly less pain and quality of life improved. Sclerotherapy is a simple treatment modality, it is relatively inexpensive but still requires doctor's expertise and the use of proper equipment.

The authors declare no conflict of interest.

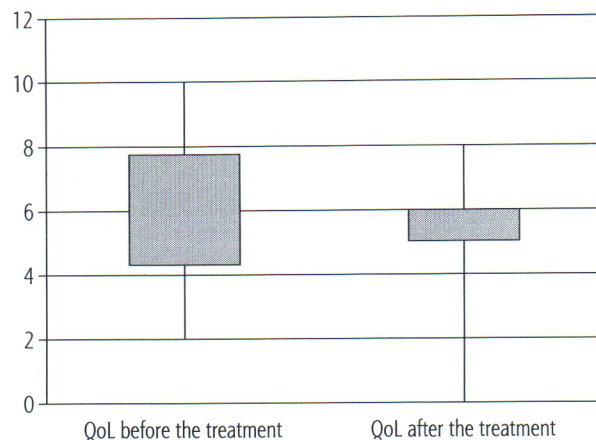


Fig. 8. Quality of life (QoL) in patients managed with other methods (control group)

References

- Rybak Z., Szczepkowski M., Sajdak S. oraz Grupa Robocza Ekspertów. Wytyczne diagnostyki i leczenia choroby hemoroidalnej. *Phlebol Rev* 2008; 16: 7-12.
- Madoff R.D., Fleshman J.W.; Clinical Practice Committee, American Gastroenterological Association. American Gastroenterological Association technical review on the diagnosis and treatment of hemorrhoids. *Gastroenterology* 2004; 126: 1463-1473.
- Hubner K. Sclerotherapy of hemorrhoids. In: Hubner K. (ed.). *Sclerotherapy in practice*. Viavital Verlag GmbH, Essen 2007.
- Brühl R., Schmauz W. Injection sclerotherapy and a bulk laxative in the treatment of bleeding grade 1 hemorrhoids. *Coloproctology* 2000; 22: 211-217.
- Akerud L. Skleroterapia guzków krwawniczych odbytu – prospektywne randomizowane badanie polidocanolu i fenolu w oleju. *Phlebol Rev* 2006; 14: 247-257.
- Moser K.-H. Ocena skuteczności i bezpieczeństwa skleroterapii za pomocą piany z polidokanolu krwawiących guzków krwawniczych w pierwszym stopniu. *Phlebol Rev* 2007; 15: 103-106.
- Tokunaga Y., Sasaki H., Saito T. Evaluation of sclerotherapy with a new sclerosing agent and stapled hemorrhoidopexy for prolapsing internal hemorrhoids: retrospective comparison with hemorrhoidectomy. *Dig Surg* 2010; 27: 469-472.
- Khoury G.A., Lake S.P., Lewis M.C., Lewis A.A. A randomized trial to compare single with multiple phenol injection treatment for hemorrhoids. *Br J Surg* 1985; 72: 741-742.